

## Case Report

# Petersen's Space Internal Hernia after Laparoscopic One Anastomosis (Mini) Gastric Bypass

Mohammad Kermansaravi <sup>1,2</sup>, Mohammad Kazazi,<sup>3</sup> and Abdolreza Pazouki <sup>1,2</sup>

<sup>1</sup>Minimally Invasive Surgery Research Center, Iran University of Medical Sciences, Tehran, Iran

<sup>2</sup>Center of Excellence of International Federation for Surgery of Obesity, Hazrat-e Rasool Hospital, Tehran, Iran

<sup>3</sup>Shahid Lavasani Hospital, Social Security Organization, Tehran, Iran

Correspondence should be addressed to Abdolreza Pazouki; apazouki@yahoo.com

Received 2 November 2017; Accepted 8 January 2018; Published 1 April 2018

Academic Editor: Boris Kirshtein

Copyright © 2018 Mohammad Kermansaravi et al. This is an open access article distributed under the Creative Commons Attribution License, which permits unrestricted use, distribution, and reproduction in any medium, provided the original work is properly cited.

**Background.** One anastomosis gastric bypass (OAGB) is now considered as an appropriate alternative for Roux-en-Y gastric bypass (RYGB) with some advantages such as absence of risk for internal hernia (IH). But, is really the risk of IH equal zero after OAGB? **Case Summary.** A 37-year-old male was admitted due to severe abdominal crampy pain, nausea, vomiting, and obstipation. He had chronic and intermittent abdominal pain from 2 years after OAGB. With high suspicion of complete obstruction, the exploratory laparoscopy was performed. Intraoperative findings showed incarcerated bowel hernia from Petersen's defect. The incarcerated bowel was reduced, and the defect was repaired. The patient was discharged 2 days after operation. **Conclusion.** The incidence of IH after OAGB is rare but not zero. In any suspicious signs and symptoms for IH, the early exploratory laparoscopy is mandatory to diagnose and treat.

## 1. Introduction

One anastomosis gastric bypass (OAGB) or mini-gastric bypass is now accepted around the world as an alternative method for Roux-en-Y gastric bypass (RYGB), the gold standard method of bariatric surgery, with comparable efficacy and safety and some advantages to RYGB [1, 2]. Absence of internal hernia is considered as one of the advantages of OAGB in long-term follow-ups [1–3]. Petersen's space is the space between the afferent loop mesentery of gastrojejunostomy and the lower part of transverse colon mesentery that is created after gastrojejunostomy in some procedures such as RYGB and OAGB [3, 4]. Till now, only two Petersen's space hernia (PH) after OAGB are reported [3, 5] showing that PH occurrence is rare after OAGB; however, it is not impossible.

## 2. Case Presentation

A 37-year-old male, with body mass index (BMI) of 27 kg/m<sup>2</sup>, was admitted in emergency department with severe crampy abdominal pain, nausea, vomiting, and obstipation from 2 days

before admission. He had a history of OAGB (with concomitant Braun jejunostomy 30 cm below the gastrojejunostomy) 3 years ago. Twenty-seven months after OAGB, he had complaints of crampy and intermittent left upper quadrant (LUQ) abdominal pain episodes, which led to two times hospital admissions before. Clinical and paraclinical evaluations such as upper endoscopy, abdominal ultrasonography, abdominal radiographies, and computed tomography (CT) scan with IV/PO contrast had reported normal findings. One of his abdominal plain X-rays is shown in Figure 1. The patients had a BMI loss of 20.9 kg/m<sup>2</sup> during 3 years after surgery.

During this admission, on physical examination, he had normal temperature, blood pressure, and respiratory rate; however, he had tachycardia (HR: 110/min). The abdomen was distended without any tenderness and guarding.

## 3. Management

Due to high suspicion of complete obstruction, after initial resuscitation, the patient underwent exploratory laparoscopy.

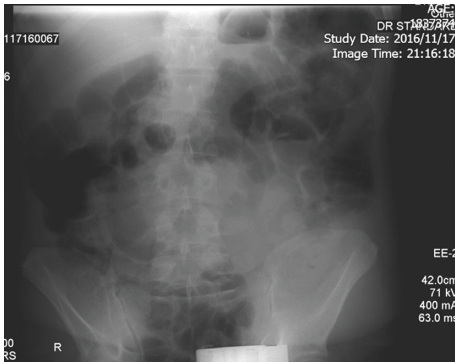


FIGURE 1: Plain abdominal X-ray during abdominal pain attack.

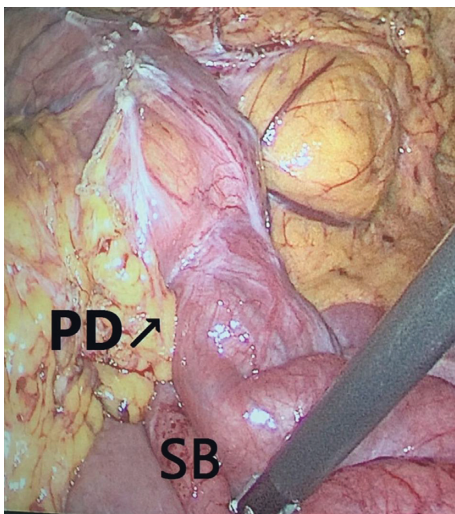


FIGURE 2: Intraoperative view of IH that shows herniated small bowel (SB) through Petersen's defect (PD).

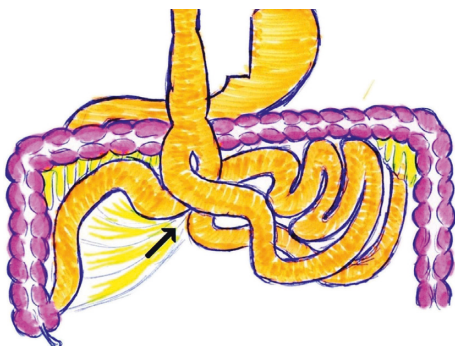


FIGURE 3: Schematic picture in this case shows the herniation of whole small bowel from Petersen's space (arrow).

During laparoscopy, most of the small bowel had been passed through the Petersen's space from right to left and was incarcerated with few patchy lesions in some sites of the small bowel without any sign of severe ischemia and gangrene (Figures 2 and 3). The incarcerated bowel was reduced, and the defect was sewn with Prolene 2-0. Also Braun's jejunojunal

defect was closed in order to prevent the subsequent IH. He was discharged 2 days after operation and had no problem till 6 months of follow-up.

#### 4. Discussion

Internal hernia (IH) occurs after some malabsorptive surgical procedures such as RYGB [3], with an incidence between 0.9% and 11.7%, if the defect was not closed after RYGB [6–8]. Defect closure can reduce the incidence of IH but cannot eliminate it [7, 9]. Aghajani et al. in a study with 60 months of follow-up on 2443 patients who underwent LRYGB showed that defect closure leads to reduction of IH incidence from 11.7% to 2.5% and 4.09-fold decrease of relative risk for IH [7].

Due to longer pouch creation in OAGB in comparison to RYGB and therefore larger Petersen's space, the risk of incarceration and strangulation is very low [2], as in two past case reports, there was no evidence of bowel ischemia [3, 5]. Although in this case that the most of the bowel length was herniated, it is possible to have incarceration and ischemia. On the other hand, the rare incidence of IH after OAGB and the fact that defect closure addition to operating time elongation may lead to some complications such as mesenteric bleeding and hematoma, kinking and rotation of anastomosis, and also adhesion formation [10]; it could not be recommended to routine closure of Petersen's space during OAGB; however, in presence of more possible reports over time, the traditional approach needs to be changed.

The most important lesson is that chronic and intermittent abdominal pain, especially in LUQ, and also nausea especially after meal, can be a presentation of IH after RYGB and OAGB [3–5]. Up to 20% of IH could have normal findings in CT scan and small bowel series [4], so in high suspicious conditions for IH, as the same as RYGB, prompt explorative laparoscopy is necessary for the achievement of definite diagnosis and appropriate treatment to prevent possible serious complications [4, 10].

#### Conflicts of Interest

The authors declare that they have no conflicts of interest.

#### Authors' Contributions

Mohammad Kermansaravi, Mohammad Kazazi, and Abdolreza Pazouki developed the idea and concept. Mohammad Kermansaravi, Mohammad Kazazi, and Abdolreza Pazouki wrote the proposal. Mohammad Kermansaravi and Abdolreza Pazouki were involved in data gathering. Data clearance was done by Mohammad Kermansaravi and Mohammad Kazazi. Data preparation for analysis was done by Mohammad Kermansaravi and Abdolreza Pazouki. First drafting of the manuscript was done by Mohammad Kermansaravi, Mohammad Kazazi, and Abdolreza Pazouki did the first drafting of the manuscript. Mohammad Kermansaravi, Mohammad Kazazi, and Abdolreza Pazouki guaranteed

all contents of the manuscript. Mohammad Kermansaravi and Mohammad Kazazi contributed equally to this article.

## References

- [1] J. M. Chevallier, G. A. Arman, M. Guenzi et al., "One thousand single anastomosis (omega loop) gastric bypasses to treat morbid obesity in a 7-year period: outcomes show few complications and good efficacy," *Obesity Surgery*, vol. 25, no. 6, pp. 951–958, 2015.
- [2] K. K. Mahawar, W. R. J. Carr, S. Balupuri, and P. K. Small, "Controversy surrounding 'mini' gastric bypass," *Obesity Surgery*, vol. 24, no. 2, pp. 324–333, 2014.
- [3] L. Genser, S. Carandina, and A. Soprani, "Petersen's internal hernia complicating a laparoscopic omega loop gastric bypass," *Surgery for Obesity and Related Diseases*, vol. 11, no. 5, pp. e33–e34, 2015.
- [4] K. D. Higa, T. Ho, and K. B. Boone, "Internal hernias after laparoscopic Roux-en-Y gastric bypass: incidence, treatment and prevention," *Obesity Surgery*, vol. 13, no. 3, pp. 350–354, 2003.
- [5] E. Facchiano, A. Iannelli, and M. Lucchese, "Internal hernia after mini-gastric bypass: myth or reality?," *Journal of Visceral Surgery*, vol. 153, no. 3, pp. 231–232, 2016.
- [6] M. Cho, D. Pinto, L. Carrodeguas et al., "Frequency and management of internal hernias after laparoscopic antecolic antegastric Roux-en-Y gastric bypass without division of the small bowel mesentery or closure of mesenteric defects: review of 1400 consecutive cases," *Surgery for Obesity and Related Diseases*, vol. 2, no. 2, pp. 87–91, 2006.
- [7] E. Aghajani, B. J. Nergaard, B. G. Leifson, J. Hedenbro, and H. Gislason, "The mesenteric defects in laparoscopic Roux-en-Y gastric bypass: 5 years follow-up of non-closure versus closure using the stapler technique," *Surgical Endoscopy*, vol. 31, no. 9, pp. 3743–3748, 2017.
- [8] R. W. Bauman and J. R. Pirrello, "Internal hernia at Petersen's space after laparoscopic Roux-en-Y gastric bypass: 6.2% incidence without closure—a single surgeon series of 1047 cases," *Surgery for Obesity and Related Diseases*, vol. 5, no. 5, pp. 565–570, 2009.
- [9] M. R. Al-Mansour, R. Mundy, J. M. Canoy, K. Dulaimy, J. N. Kuhn, and J. Romanelli, "Internal hernia after laparoscopic antecolic Roux-en-Y gastric bypass," *Obesity Surgery*, vol. 25, no. 11, pp. 2106–2111, 2015.
- [10] E. Aghajani, H. J. Jacobsen, B. J. Nergaard, J. L. Hedenbro, B. G. Leifson, and H. Gislason, "Internal hernia after gastric bypass: a new and simplified technique for laparoscopic primary closure of the mesenteric defects," *Journal of Gastrointestinal Surgery*, vol. 16, no. 3, pp. 641–645, 2012.



**Hindawi**

Submit your manuscripts at  
[www.hindawi.com](http://www.hindawi.com)

