



Successful Laparoscopic Right Adrenalectomy in a Morbidly Obese Patient with a Large Liver: A Case Report

Mohammad Kermansaravi,¹ Sattar Darabi,¹ Alireza Khalaj,^{2,*} Abdolreza Pazouki,^{3,4,5} and Ali Kabir⁶

¹MD, Minimally Invasive Surgery Research Center, Iran University of Medical Sciences, Tehran, Iran

²MD, Tehran Obesity Treatment Center, Department of Surgery, Shahed University, Tehran, Iran

³MD, Associate Professor of Minimally Invasive Surgery, Minimally Invasive Surgery Research Center, Iran University of Medical Sciences, Tehran, Iran

⁴Head, Center of Excellence for Minimally Invasive Surgery Training, Iran University of Medical Sciences, Tehran, Iran,

⁵Center of Excellence of European Branch of International Federation for Surgery of Obesity, Tehran, Iran

⁶MD, MPH, PhD, Assistant Professor of Epidemiology, Minimally Invasive Surgery Research Center, Iran University of Medical Sciences, Tehran, Iran

*Corresponding author: Alireza Khalaj, Minimally Invasive Surgery Research Center, Mansouri Alley, Niyayesh St, Sattarkhan St, Tehran, Iran. Tel: +98-2144468645, Fax: +98-2144476796, E-mail: khalaj@totc.ir

Received 2016 September 21; Revised 2016 October 31; Accepted 2017 July 15.

Abstract

Introduction: Laparoscopic adrenalectomy is a safe procedure that was performed in 1992 for the first time. Morbid obesity is an independent risk factor for complications of adrenalectomy in postoperative period and conversion of laparoscopy to open procedure. Recent data show that laparoscopic adrenalectomy can reduce the recovery time, wound complications and hospital stay in morbidly obese and diabetic patients.

Case Presentation: A 37-year-old morbidly obese diabetic female that was a candidate for bariatric surgery with chief complaint of right flank pain and large complex adrenal mass in preoperative ultrasonography confirmed by CT-scan and MRI was the case of this study. The patient underwent laparoscopic lateral transabdominal adrenalectomy and was discharged two days after operation without any complications. The pathologic study report was myelolipoma.

Conclusions: Laparoscopic adrenalectomy may be considered as a safe procedure in morbidly obese patients and can reduce the perioperative complications and recovery period in comparison with the open approach.

Keywords: Laparoscopy, Adrenalectomy, Obesity, Morbid, Myelolipoma, Hepatomegaly

1. Introduction

Gagner et al. performed the first laparoscopic adrenalectomy in 1992 (1). Today, it is usually performed in two minimally invasive approaches: the posterior retroperitoneal and the lateral transabdominal approach. The choice of approach is dependent upon the patient, tumor criteria, and the surgeon's experience. The lateral transabdominal approach has preference for large tumors, morbidly obese patients, and when malignancy is suspected.

Morbid obesity is an independent risk factor for complications of adrenalectomy such as wound infection and sepsis in postoperative period, and can increase the operation time and risk of conversion of laparoscopy to open procedure. Also, diabetes mellitus can increase wound complications (2).

Recent data show that laparoscopic adrenalectomy can reduce the risk of intraoperative bleeding, recovery time, wound complications, analgesic need, and hospital stay in

morbidly obese and diabetic patients (3).

Some investigators explained one stage bariatric surgery and laparoscopic adrenalectomy in morbidly obese patients (4, 5).

In addition to morbid obesity, large liver, big tumors and surgeon's insufficient experience are factors that can increase the risk of conversion to open surgery (6, 7).

The new advances in imaging tools such as ultrasonography, computed tomography (CT) scan, and magnetic resonance imaging (MRI) have resulted in more accurate diagnosis of adrenal tumors (8).

2. Case Presentation

A 37-year-old morbidly obese diabetic female with body mass index (BMI) = 47 that was candidate for bariatric surgery and had a complaint of right flank pain was the case of this study. In preoperative phase, we found a large complex adrenal mass in her ultrasonography result that was suspected for pheochromocytoma or malignancy.

In adrenal T2W MRI, the patient had an $82 \times 78 \times 55$ mm heterogeneous mass in right adrenal gland that was suspected to myelolipoma, pheochromocytoma or malignancy (Figure 1).

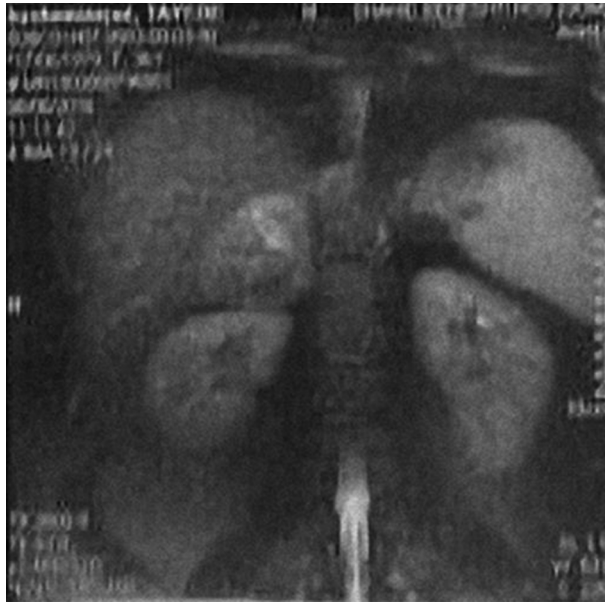

Figure 1. T2W MRI, Right Heterogeneous Adrenal Mass

In abdominal CT scan, the mass was reported suspicious for malignancy or myelolipoma (Figure 2).

In laboratory findings, we found normal hormonal assay that is listed in Table 1.

Table 1. Biochemical and Hormonal Assay

Test	Result	Unit	Normal Ranges
FBS	341	mg/dL	70 - 115
Sodium	134	mmol/L	135 - 145
Potassium	4.1	mmol/L	3.5 - 5.5
Urine 24h/metanephrine	94.2	μ gr/24h	0 - 350
Urine 24h/Cr	504	mg/24h	600 - 1800
Cortisol 8 AM	24.5	μ gr/dL	5 - 25
Aldosterone (upright)	61.8	pg/mL	25 - 315
ACTH	15.57	pg/mL	4.7 - 48.8

Abbreviations: ACTH, Adrenocorticotropic Hormone; Cr, Creatinine; dL, Deciliter; FBS, Fasting Blood Sugar; L, Liter; mg, Milligram; mL, Milliliter; mmol, Milimol; pg, Pictograms; μ gr, Micrograms.

The patient was scheduled for laparoscopic lateral transabdominal adrenalectomy. After intubation, under general anesthesia, in lateral decubitus position, we in-

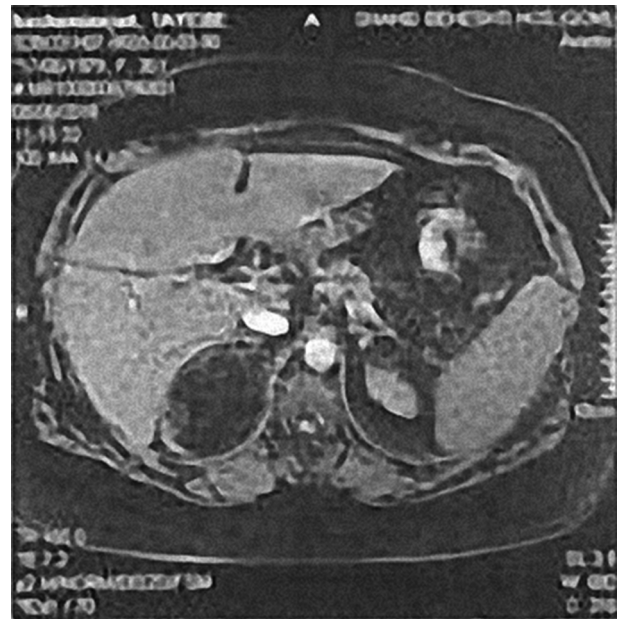


Figure 2. Abdominal CT, Right Adrenal Heterogeneous Mass with Variable Central and Peripheral Attenuation

serted the first 12 mm trocar in open technique in midclavicular line. 2 cm under costal margin, and after insufflation of CO₂, we inserted next three 5 mm trocars. The patient had a very large liver and after division of triangular ligament from inferior border of liver, we used a grasper from the most medial trocar near epigastrium to elevate the liver for good exposure. Then, we explored the lateral border of inferior vena cava (IVC), right renal vein, and right adrenal vein. Then, the adrenal vein and subsequently the adrenal arteries were clipped and divided. Finally, adrenalectomy was done and we substituted the 10 mm lens with the 5 mm one and extracted the specimen in endobag from the 12 mm trocar (Figures 3, 4). The patient was discharged two days after the operation without any complications. The pathologic study report was myelolipoma. The patient had no complication after a 3-month follow up. Informed consent was obtained from the patient and her spouse for publication of this manuscript and related images.

3. Discussion

Laparoscopic adrenalectomy is a safe approach and was introduced in 1992 for the first time (1). Also, Morbid obesity is an independent risk factor for complications of adrenalectomy in the postoperative period. It is a risk factor for conversion to open procedure, especially in pres-

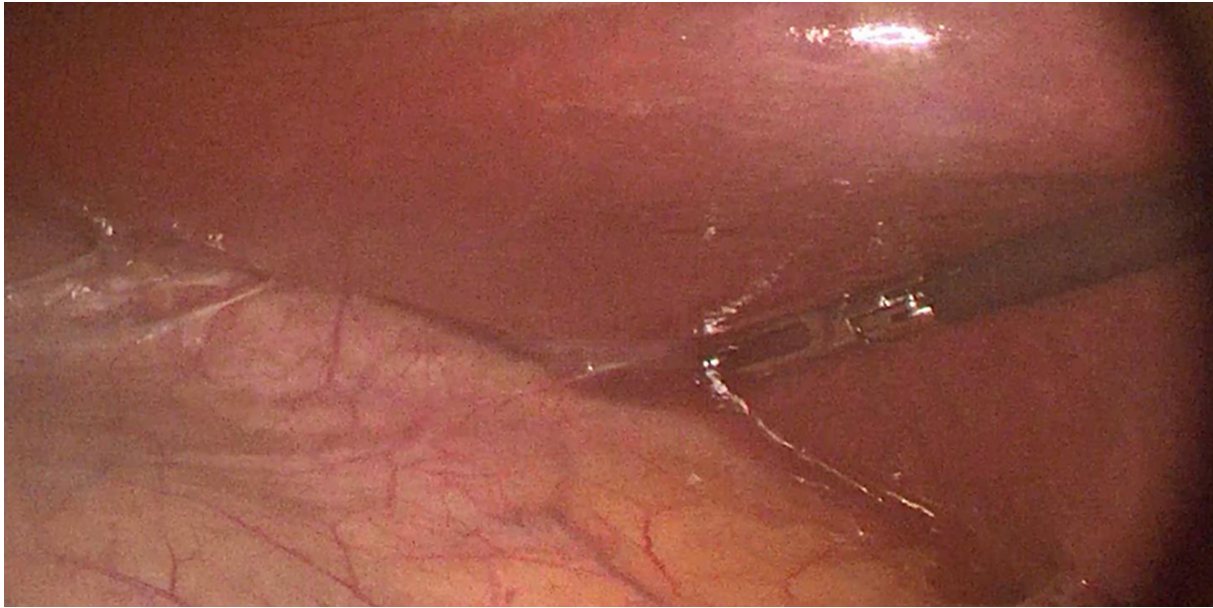


Figure 3. Large Liver

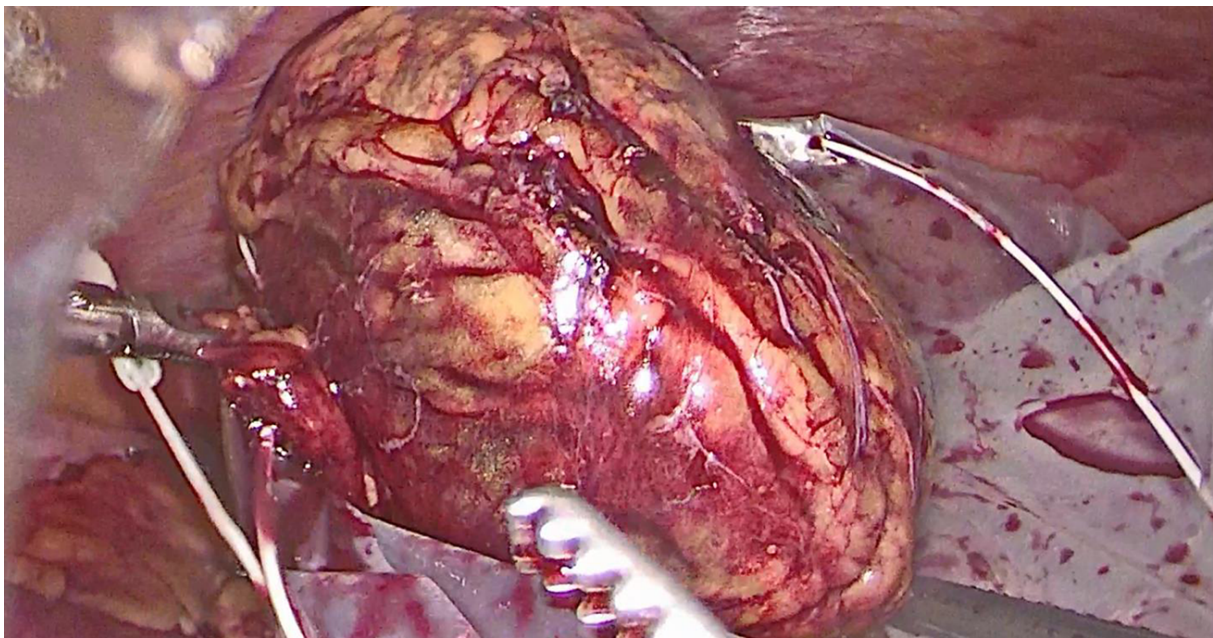


Figure 4. Extraction of Specimen

ence of large liver (hepatomegaly), large tumors, and the surgeon's insufficient experience (2, 6).

But successful laparoscopic procedure for adrenal tumors can reduce the post-operative complications in morbidly obese patients (3).

Amador G. Ruiz de Gordejuela et al. reported successful one stage laparoscopic left adrenalectomy in addition to sleeve gastrectomy in a morbidly obese patient by supra-gastric approach (4).

Sergio Jose Bardaro et al. performed laparoscopic left

adrenalectomy for a cortical adenoma during Roux-en-Y gastric bypass in a morbidly obese patient without any later complications (5).

Rodriguez-Hermosa et al. reported a safe laparoscopic adrenalectomy in a morbidly obese patient with a large pheochromocytoma without any complications in a 6-month follow up (6).

3.1. Conclusion

Laparoscopic adrenalectomy may be a safe procedure with good results in morbidly obese patients even in presence of large liver and can reduce the postoperative complications as well as the recovery period in comparison with the open approach especially in diabetic patients.

In fact, morbid obesity, large liver, and big tumors only can harden the laparoscopic procedure but are not contraindications for it.

Acknowledgments

We acknowledge Maryam Beitollahi for her assistance in English editing and submitting the manuscript.

Footnotes

Authors' Contribution: Designing the study and presenting the case, Mohammad Kermansaravi, Ali Kabir, Abdolreza Pazouki, Alireza Khalaj, Sattar Darabi; drafting the paper, Mohammad Kermansaravi, Ali Kabir; contributing to the data collection, literature review and writing-up process, Mohammad Kermansaravi, Ali Kabir, Sattar Darabi, Abdolreza Pazouki, Alireza Khalaj; reading and approving

the final manuscript, Mohammad Kermansaravi, Ali Kabir, Sattar Darabi, Abdolreza Pazouki, Alireza Khalaj.

Conflict of Interests: Authors declare no conflict of interest.

Financial Disclosure: None declared.

References

1. Lan BY, Taskin HE, Aksoy E, Birsan O, Dural C, Mitchell J, et al. Factors affecting the surgical approach and timing of bilateral adrenalectomy. *Surg Endosc.* 2015;**29**(7):1741-5. doi: [10.1007/s00464-014-3891-1](https://doi.org/10.1007/s00464-014-3891-1). [PubMed: [25361646](https://pubmed.ncbi.nlm.nih.gov/25361646/)].
2. Kazaure HS, Roman SA, Sosa JA. Obesity is a predictor of morbidity in 1,629 patients who underwent adrenalectomy. *World J Surg.* 2011;**35**(6):1287-95. doi: [10.1007/s00268-011-1070-2](https://doi.org/10.1007/s00268-011-1070-2). [PubMed: [21455782](https://pubmed.ncbi.nlm.nih.gov/21455782/)].
3. Fazeli-Matin S, Gill IS, Hsu TH, Sung GT, Novick AC. Laparoscopic renal and adrenal surgery in obese patients: comparison to open surgery. *J Urol.* 1999;**162**(3 Pt 1):665-9. doi: [10.1097/00005392-199909010-00005](https://doi.org/10.1097/00005392-199909010-00005). [PubMed: [10458337](https://pubmed.ncbi.nlm.nih.gov/10458337/)].
4. de Gordejuela AG, Gebelli JP, Garcia NV, Medayo LS, Marin AE, Badia AC. One stage laparoscopic left adrenalectomy and sleeve gastrectomy by direct supragastric approach. *Int J Surg Case Rep.* 2014;**5**(1):22-5. doi: [10.1016/j.ijscr.2013.11.008](https://doi.org/10.1016/j.ijscr.2013.11.008). [PubMed: [24394858](https://pubmed.ncbi.nlm.nih.gov/24394858/)].
5. Bardaro SJ, Gagner M. Laparoscopic left adrenalectomy during Roux-en-Y gastric bypass using a supragastric approach. *Obes Surg.* 2006;**16**(7):919-23. doi: [10.1381/09608920677822403](https://doi.org/10.1381/09608920677822403). [PubMed: [16839494](https://pubmed.ncbi.nlm.nih.gov/16839494/)].
6. Rodriguez-Hermosa JI, Roig-Garcia J, Girones-Vila J, Ruiz-Feliu B, Costa-Lima E, Recasens-Sala M, et al. Laparoscopic adrenalectomy for a large pheochromocytoma in a morbidly obese patient. *Obes Surg.* 2010;**20**(8):1195-7. doi: [10.1007/s11695-008-9744-z](https://doi.org/10.1007/s11695-008-9744-z). [PubMed: [18946709](https://pubmed.ncbi.nlm.nih.gov/18946709/)].
7. Shen ZJ, Chen SW, Wang S, Jin XD, Chen J, Zhu Y, et al. Predictive factors for open conversion of laparoscopic adrenalectomy: a 13-year review of 456 cases. *J Endourol.* 2007;**21**(11):1333-7. doi: [10.1089/end.2006.450](https://doi.org/10.1089/end.2006.450). [PubMed: [18042025](https://pubmed.ncbi.nlm.nih.gov/18042025/)].
8. Nabi J, Rafiq D, Authoy FN, Sofi GN. Incidental detection of adrenal myelolipoma: a case report and review of literature. *Case Rep Urol.* 2013;**2013**:789481. doi: [10.1155/2013/789481](https://doi.org/10.1155/2013/789481). [PubMed: [23509660](https://pubmed.ncbi.nlm.nih.gov/23509660/)].